

About Hydrocephalus: For Parents and Patients

(also, see PowerPoint presentation [“Hydrocephalus: Practical Aspects”](#))

Joseph H Piatt, Jr, MD, FAAP
Professor of Neurological Surgery and Pediatrics
Drexel University College of Medicine
Chief, Section of Neurosurgery
St Christopher's Hospital for Children

- [What It Is](#)
- [Symptoms and signs](#)
- ["Normal pressure hydrocephalus"](#)
- [Treatment](#)
- [CSF shunt failure](#)
- [An alternative - endoscopic third ventriculostomy](#)
- [The history of CSF shunts](#)

What It Is

The diagnosis of hydrocephalus seems strange and threatening to most patients and their families, but it is a common condition. Probably as many as 2 or 3 newborns in a thousand are born with hydrocephalus, either as an isolated problem or as part of a more complicated collection of birth defects. A large number of diseases acquired later in life can cause hydrocephalus as well, so the overall prevalence in the population of the United States is about 0.5%. Most people know someone with hydrocephalus or someone who has a family member with hydrocephalus.

The word "hydrocephalus" is constructed from two roots: "-cephalus" means head. "hydro-" refers to water or, more precisely, cerebrospinal fluid (CSF). CSF is a normal, watery substance that fills the skull and the spinal canal. The brain makes CSF, and the brain and spinal cord float in it. CSF is produced within the brain in a sequence of internal cavities called ventricles. It flows from one cavity to the next through small passageways and channels [*Figure 1*]. Eventually it finds its way out of the brain, and it fills the spaces between the brain and the skull, where it is reabsorbed or recycled back into the blood stream. These processes of production and recycling go on continuously inside all of us at a rate of about 1 pint of CSF per day.

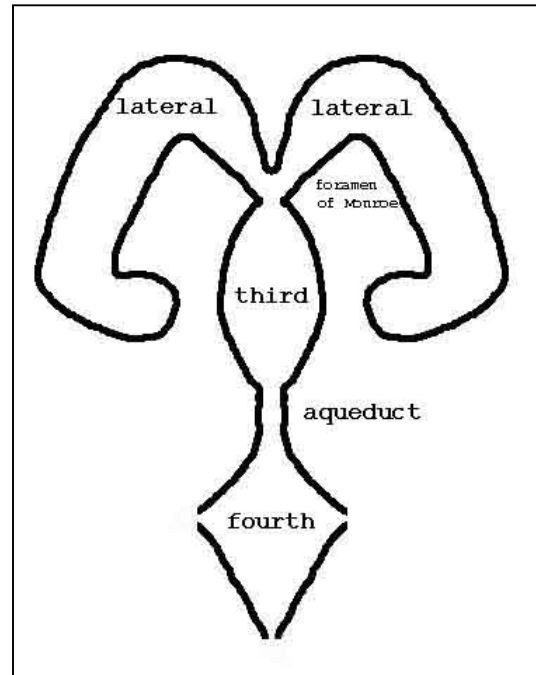


Figure 1. A schematic diagram of the ventricular system: The ventricles are normal cavities within the brain filled with watery cerebrospinal fluid (CSF), which is produced within the ventricles by specialized tissue called the choroid plexus. The lateral ventricles are paired -- right and left -- and they are far larger than the third and fourth ventricles. Each lateral ventricle drains into the third ventricle through a passageway called the foramen of Monroe. The third ventricle drains into the fourth ventricle through a narrow channel called the aqueduct of Sylvius. Openings in the corners of the fourth ventricle allow CSF to escape from the ventricular system and fill the spaces around the brain, the subarachnoid spaces. CSF is recycled out of the subarachnoid spaces into the venous side of the blood stream.

People with hydrocephalus have a problem with the balance between production and recycling of CSF. Production of CSF goes on at a constant rate regardless of other circumstances within the

body or in the environment as long as life lasts, but the recycling of CSF depends on pressure within the head: The higher the pressure, the more rapidly CSF is recycled. Normal pressures in the head range between 15 mm Hg lying down and subatmospheric levels standing up. In most of us these pressures drive enough CSF back into the blood stream to maintain a balance with CSF production. In people with hydrocephalus, however, flow of CSF between the ventricles and recycling of CSF are impaired, and higher than normal pressures within the ventricles are necessary to keep production and recycling in balance.

Symptoms and Signs

High pressure within the head and the distention of the ventricular system that usually accompanies it cause a variety of symptoms depending on age, rapidity of onset, and severity. In infancy hydrocephalus manifests itself most characteristically by accelerated head growth. The infant's soft spot, or fontanel, may be convex and tense, and in severe cases there may be irritability, vomiting, lethargy, and coma. If the symptoms are neglected or misinterpreted, hydrocephalus can be life-threatening. Later in childhood and in adult life, the rigidity of the skull may cause symptoms to progress more rapidly, but on the other hand, greater self-awareness in older children and adults may bring them to attention earlier with symptoms of headache, mental dullness, or anorexia.

The rigid skull of older patients in some cases allows pressure to rise to levels that affect vision as well. The abnormal pressure can cause swelling of the optic nerves, which are the large nerves that convey visual information from the eyes to the brain. This swelling is called papilledema, and physicians can actually see papilledema by examining the eyes carefully. The presence of papilledema can be helpful from a diagnostic standpoint, but it is also a sign of impending and potentially permanent optic nerve injury. Severe, longstanding hydrocephalus can cause blindness.

When hydrocephalus develops insidiously, and when it is only mild or moderate in degree, the symptoms may be limited to impairment of cognitive function. In adults this syndrome is called *normal pressure hydrocephalus*, because

the elevations of intracranial pressure are episodic and measurement of intracranial pressure at any single point in time is likely to be normal. The classical clinical picture of normal pressure hydrocephalus includes urinary incontinence and a distinctive pattern of gait disturbance, but these associated symptoms are of variable prominence from case to case. Because it is so readily treatable, normal pressure hydrocephalus is an important consideration in the evaluation of dementia.

Insidious development of hydrocephalus or, more often, insidious failure of treatment can come to attention with mental impairment in childhood as well, but the effects of hydrocephalus on the developing brain are somewhat different from its effects on the mature brain. Childhood hydrocephalus, particularly among patients with spina bifida, is commonly associated with a distinctive pattern of cognitive limitations referred to as nonverbal learning disabilities. The qualifier "nonverbal" reflects the relative preservation of language-related skills, and indeed the discrepancy between facility with language and other mental activities may be striking. An affected child may seem very bright and sociable in casual conversation but may fall down disastrously when asked to execute a task that requires planning an ordered sequence of actions. Nonverbal learning disabilities are present at baseline in many well-treated children, but they may be exacerbated by CSF shunt problems. School failure in a child with hydrocephalus should at least raise the question of treatment failure.

Treatment

The most common approach to treatment of hydrocephalus is to give the CSF somewhere else to go where it can be recycled at low pressure: A CSF shunt is soft plastic drain that serves as a conduit from the ventricular system to some other body cavity. The usual receptacle for shunted CSF is the peritoneal cavity, which is the hollow place in the abdomen where the stomach and the intestines churn. Hence the term ventriculoperitoneal shunt. CSF dumped into the peritoneal cavity is reabsorbed back into the blood stream across the membrane that lines it. Other options for the diversion of CSF include the pleural cavity (the hollow place in the chest

where the lungs inflate and deflate), the gall bladder, and the right atrium of the heart.

A CSF shunt is inserted by means of an operation. The ventricular segment of the shunt enters the head through a small hole in the skull, and the downstream segment proceeds to its destination under the skin. No part of it lies outside the body. The shunt includes a resistance element called a valve, which is intended to regulate how rapidly CSF drains through the system, and most shunt designs also include a bubble or reservoir that can be punctured with a needle for diagnostic purposes. The shunt can be felt, if one knows where to look for it, but it usually cannot be seen.

CSF Shunt Failure

CSF shunts meant the difference between life and death for people with hydrocephalus when they were first developed almost 50 years ago, but there were then -- and there are still -- many problems. A CSF shunt must be thought of like a toaster or a car: It does not last forever, and when it finally breaks, it must be repaired or replaced. Repair or replacement of a shunt is referred to as a revision, and unfortunately every shunt revision entails admission to hospital for an operation. The first year after surgery is the period of greatest risk for shunt failure: About 40% of shunts must be revised within the first year. If a shunt makes it through the first year, however, the risk of failure drops to 5% per year beyond that point. So roughly half of all shunts will last in service beyond 6 years.

Shunts can fail in many ways: In roughly 5% of cases, they are contaminated with germs at surgery and eventually become infected. Tissue from the walls of the ventricular cavity can grow into the little perforations at the ventricular end of the shunt, or debris in the CSF can collect at some sensitive spot and plug it up. As a shunt ages, it can become brittle, and growth or body movement can pull it apart. Shunts can actually drain too much CSF in some instances, causing symptoms from excessively low pressure inside the head or even causing intracranial hemorrhage from deflation of the brain.

When a shunt fails, the symptoms of hydrocephalus that are described above return, but a moment's reflection suggests how difficult

shunt failure can be to recognize at times. A toddler with a shunt becomes irritable and begins to vomit: Does he have an ear infection? Does he have the flu? A 12 year old with borderline intelligence begins to fail in middle school: Have the demands of school simply exceeded her mental capacities? Her mother thinks the problem is "hormones"!

The first step in the assessment of CSF shunt function is to check the volume of the ventricular system by some modality of brain imaging: ultrasound, computed tomography (CT), or magnetic resonance (MR) imaging. As a general rule, when a shunt is failing, the ventricular system is larger than it is when the shunt is working properly, but the increment in ventricular volume may be subtle. Hence the importance of maintaining reasonably current baseline brain images. If brain imaging is inconclusive, shunt patency can be checked by puncturing the reservoir of the valve with a needle, a procedure known as tapping the shunt. If CSF can be withdrawn from the shunt freely with a syringe, the ventricular segment must be unobstructed. The pressure in the reservoir can be measured through the needle, and if it is low - - and particularly if it falls as the patient arises from a recumbent to a sitting position -- the rest of the shunt system is probably unobstructed as well. Additionally, a sample of CSF can be collected through the needle to eliminate the possibility of infection. The diagnostic usefulness of a shunt tap can be enhanced by injection of a radioactive tracer: The tracer goes wherever the CSF goes, and if the shunt is functioning properly, the flow of the tracer down the shunt into the peritoneal cavity can be followed with a Geiger camera. In very obscure cases the neurosurgeon may recommend admission to an intensive care unit for continuous monitoring of intracranial pressure. If the symptoms in question can be correlated with measured pressure elevations inside the head, revision of the shunt may be beneficial.

Most CSF shunt designs include a pumping mechanism for moving CSF through the shunt. Compression of the bubble reservoir expels CSF out of the valve downstream, and as the bubble relaxes, it sucks CSF into the valve from upstream. At surgery this pumping mechanism is useful for priming the shunt, but many families - - and physicians too -- have latched onto it as a test of shunt function. The notion is that if CSF

can be expelled from the bubble without pumping too hard, the shunt must be open downstream, and if the bubble refills promptly, the shunt must be open upstream. In fact, pumping the shunt is a very unreliable indicator of shunt function. Many working shunts refill very slowly because the ventricular cavity in which the intracranial segment of the shunt lies is collapsed. Nor is pumping the shunt a very sensitive detector of shunt obstruction. Pumping the shunt should never substitute for a real diagnostic investigation in the face of serious concerns about shunt failure.

A comfortable and confident relationship with a neurosurgeon is the keystone of the management of hydrocephalus. This discussion of the complications of CSF shunts and the difficulties of the assessment of shunt function offers a taste of the frustrations that some people with hydrocephalus and their families may encounter. Episodes of shunt failure can be very stressful for all parties involved, including the neurosurgeon, and in such times the importance of effective communication cannot be overstated. Families must have ready access to their neurosurgeon. Symptoms must be reported, and concerns must be expressed. The neurosurgeon who listens to family members is taking advantage of one of the best tests of shunt function. Clinical research has shown that experienced parents are better judges of shunt function than pediatricians, and their opinions are at least as accurate as brain imaging! So open channels are critical both for timely intervention when the problems are real and for authoritative reassurance when they are not.

An Alternative

In certain cases hydrocephalus can be managed without a shunt. If the obstruction to the drainage of CSF is located in or around the fourth ventricle, it can be bypassed by the surgical creation of a new drainage route through the floor of the third ventricle, a third ventriculostomy. Causes of hydrocephalus that can commonly be treated in this fashion include spina bifida (the Chiari type II malformation), aqueductal stenosis, and tumors in the region of the aqueduct or the fourth ventricle.

Third ventriculostomy is performed by means of an endoscope, which is a narrow surgical

telescope that allows inspection of the interior of body cavities through small openings. The neurosurgical endoscope can be inserted into a lateral ventricle just like the ventricular segment of a shunt. The neurosurgeon then gently advances the endoscope into the third ventricle through the foramen of Monroe [Figure 2]. In suitable cases of hydrocephalus, the third ventricle has been distended, and the floor is thin, even transparent [Figure 3]. Through the endoscope the neurosurgeon can use a variety of instruments, typically a blunt probe for puncturing the floor of the third ventricle [Figure 4] and an inflatable balloon for enlarging the hole [Figure 5]. The operation is concluded when the neurosurgeon can navigate the endoscope through the hole to obtain an unobstructed view of the local anatomy of the base of the skull [Figure 6a and 6b].

Third ventriculostomy is obviously a more aggressive operation than CSF shunt insertion, and it carries greater risk. The region of the brain that lies around the third ventricle, called the hypothalamus, is responsible for various aspects of housekeeping in the body: regulation of blood pressure and heart rate, regulation of thirst and appetite, and regulation of the production of various hormones. In about 5% of cases, third ventriculostomy will disrupt some aspect of hypothalamic function. The complications seen most commonly are a disturbance of appetite with weight gain and a particular hormonal disturbance, called diabetes insipidus, that causes excessive urine production. These complications can be managed by dietary restrictions and hormonal supplementation, respectively, but they are bothersome. The most threatening complication of third ventriculostomy is injury of the basilar artery, a large artery at the base of the brain immediately beneath the floor of the third ventricle. Injury of the basilar artery can be disabling and even life-threatening. Fortunately this complication is rare, but precise statistics are not available.

Third ventriculostomy is not effective for every case of hydrocephalus. Results in infants have not been as good as in older patients, and many neurosurgeons have been reluctant to offer third ventriculostomy to patients younger than 6 months of age. There is still uncertainty about the effectiveness of third ventriculostomy in cases of hydrocephalus arising after spillage of blood in the CSF from various causes or after

meningitis. Logically, hydrocephalus caused by tumors arising in or around the fourth ventricle should respond readily to third ventriculostomy, and experience has shown that many cases of hydrocephalus related to spina bifida can be managed successfully, especially in older children and adults as an alternative to CSF shunt revision. In selected patients the success rate of third ventriculostomy is about 70%.

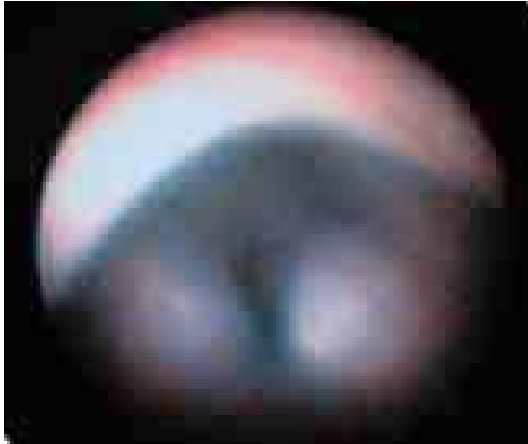

Figure 2. The tip of the endoscope lies in the lateral ventricle, and through the foramen of Monroe, the paired mammillary bodies in the floor of the third ventricle are coming into view. The view is oriented as though the patient's nose is upward.

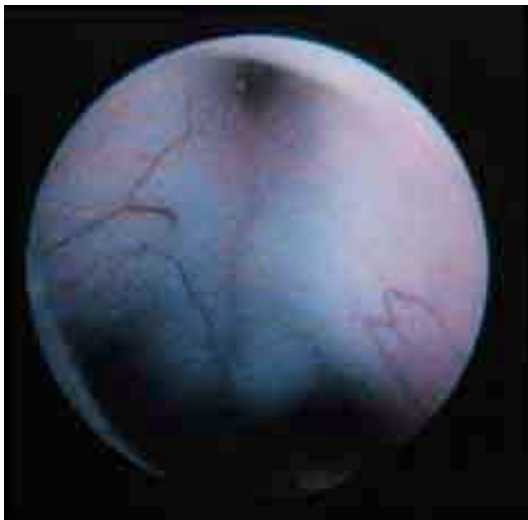

Figure 3. The tip of the endoscope now lies in the third ventricle. The anterior portion of the floor of the third ventricle is visible. Posteriorly the floor becomes quite thin and translucent.

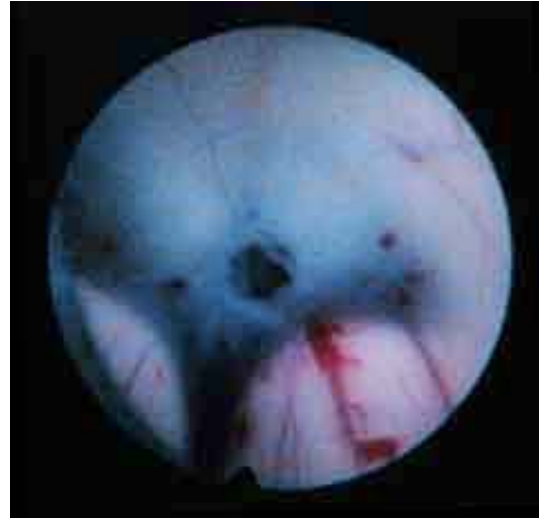


Figure 4. The tip of the endoscope is still in the third ventricle, and the posterior portion of the floor is now in view. A small hole has been made through the thin, translucent portion of the floor using a blunt probe. The paired mammillary bodies mark the posterior border of the floor of the third ventricle.

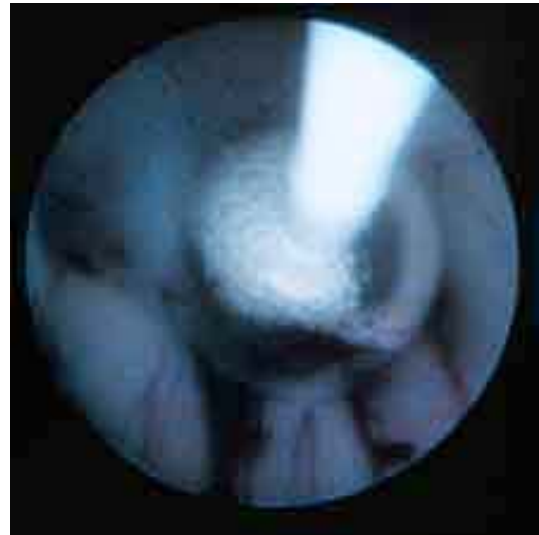

Figure 5. In the photograph on the left, a balloon-tipped catheter has been advanced through the endoscope into the third ventricle to enlarge the hole in the floor.

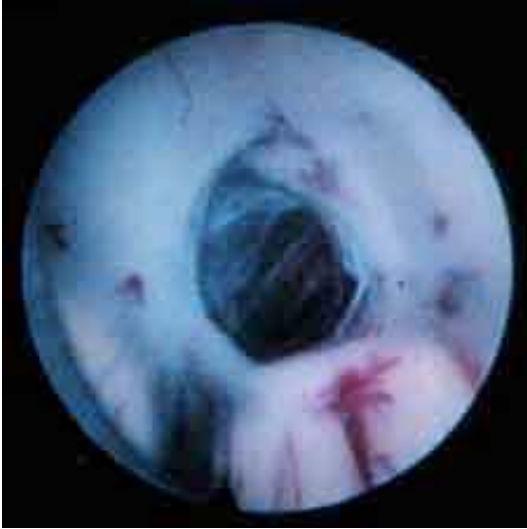

Figure 6a. The opening from the third ventricle into the subarachnoid spaces at the base of the brain allows CSF to drain directly from the ventricular system into the cisterns outside the brain. Small arterial branches of the basilar artery are faintly visible through the opening.

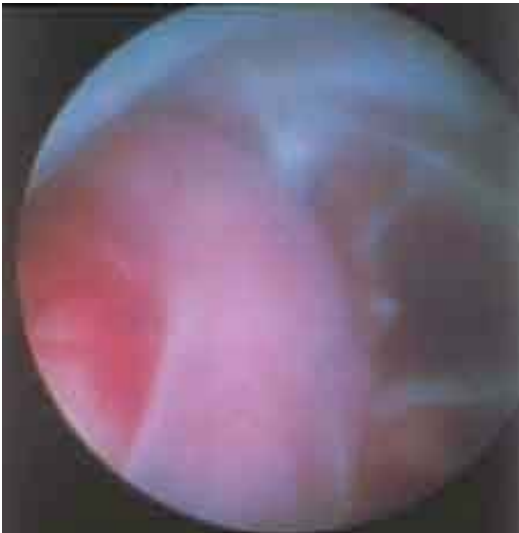

Figure 6b. The tip of the endoscope has now been advanced through the opening in the floor, and one of the large arteries at the base of the skull, the basilar artery, is visible.

Although the risks attached to third ventriculostomy are greater than the risks of a single CSF shunt operation, and although success is not assured, it is still a good choice for

many patients. For many people dependency on the function of an implanted gadget, such as a CSF shunt, is an unacceptable burden. Furthermore, third ventriculostomy is not an alternative to a single CSF shunt operation but to a lifetime of shunt operations. The lifetime risk of disability or death from complications of shunt treatment of hydrocephalus is comparable to -- perhaps greater than -- the risks of third ventriculostomy. On the other hand, as more experience with third ventriculostomy has accumulated, neurosurgeons have begun to realize that this procedure cannot be considered a cure. Relapses of active hydrocephalus have occurred after years of clinical stability following third ventriculostomy, and a small number of late deaths have been reported. Third ventriculostomy does not eliminate the need for life-long neurosurgical follow-up.

Long-term Outlook

Many people with hydrocephalus have normal intelligence, participate in all aspects of social life, and pay taxes; however, prospects for mental development and life expectancy depend much more on the nature of the underlying condition responsible for hydrocephalus than on the hydrocephalus itself. No generalizations are possible, and consultation must be sought from a neurologist or neurosurgeon.

The History of CSF Shunts

The concept of a permanent CSF shunt for hydrocephalus is at least 100 years old, but the pioneering surgeons who attempted this form of treatment were bedeviled by inadequate biomaterials. Glass and various metals were used to fabricate tubular conduits for CSF drainage to various body cavities. When these devices did not become occluded or infected, they allowed too much CSF to drain too quickly. Although the descriptions of clinical results in these old publications sound quaint today, the demise of many patients with severe hydrocephalus was probably hastened by sudden collapse of massively dilated ventricles with catastrophic subdural hemorrhage.

The first modern CSF shunts were described in 1952 by 2 Philadelphia neurosurgeons, Frank Nulsen and Eugene Spitz. Their shunt design consisted of a simple polyethylene tube that

drained the lateral ventricle into the jugular vein. Because the difference in pressure between the head and the jugular vein was not so great, excessive CSF drainage was not a prohibitive problem, but this apparatus was plagued by reflux of venous blood and clotting.

The crucial technological advance in the treatment of hydrocephalus -- arguably the only important technological advance in the history of the field to the present time -- was made by a high school-educated parent. In 1955 a child with myelomeningocele and hydrocephalus was born to John Holter, a technician in a Philadelphia machine shop. When, with the assistance of the child's neurosurgeons, he had grasped the nature of the problem, Holter

retreated to his garage workshop. He emerged some months later with a shunt design that has been in continuous use around the globe virtually unimproved for the past half century. His contributions were the development of a one-way slit valve and the identification of silicone as the optimal biomaterial for shunt fabrication. Holter's child benefited briefly from the implantation of his valve only to die subsequently from complications of shunt revisions; nevertheless, his ingenuity opened the modern era of CSF shunting as a practical treatment for hydrocephalus. This credit he shares with Robert Pudenz, a California neurosurgeon, who developed a silicone slit valve independently at about the same time.

Drexel University College of Medicine Pediatric Neurosurgery [HOME](#)

[warning!](#)